

Diagnostic discordance between MRI and histology in suspected malignant transformation of osteochondromas: a retrospective review

Adrian Jansen van Rensburg,^{1*} Karolina Siwicka,² Edward J Fúzy,¹ Rudolph G Venter,¹ Nando Ferreira¹

¹ Division of Orthopaedic Surgery, Department of Surgical Sciences, Faculty of Medicine and Health Sciences, Tygerberg Hospital, Stellenbosch University, Cape Town, South Africa

² Paley European Institute, Warsaw, Poland; Gdansk Medical University, Gdansk, Poland

*Corresponding author: adrian.jansenvanrensborg@gmail.com

Citation: Jansen van Rensburg A, Siwicka K, Fúzy EJ, Venter RG, Ferreira N. Diagnostic discordance between MRI and histology in suspected malignant transformation of osteochondromas: a retrospective review. SA Orthop J. 2026;25(2):85-88. <http://dx.doi.org/10.17159/2309-8309/2026/v25n2a6>

Editor: Dr Thomas Hilton, University of Cape Town, Cape Town, South Africa

Received: October 2024

Accepted: July 2025

Published: May 2026

Copyright: © 2026 Jansen van Rensburg A. This is an open-access article distributed under the terms of the Creative Commons Attribution Licence, which permits unrestricted use, distribution and reproduction in any medium, provided the original author and source are credited.

Funding: No funding was received for this study.

Conflict of interest: The authors declare they have no conflicts of interest that are directly or indirectly related to the research.

Abstract

Background

Accurately identifying malignant transformation in osteochondromas remains a clinical challenge, particularly due to variability in cartilage cap thickness measurements on magnetic resonance imaging (MRI). This study evaluates the concordance between MRI findings as reported by radiologists and histological diagnosis of surgically resected osteochondromas.

Methods

A single-centre retrospective cohort study was conducted on patients diagnosed with an osteochondroma from January 2016 to June 2024. Patients were diagnosed with an osteochondroma based on plain film radiographs (X-rays). MRI scan results were reviewed, as reported by experienced radiologists from an academic radiology department. Histological reports from all surgically excised osteochondromas were reviewed and compared to preoperative MRI reports.

Results

Forty-two patients with radiologically confirmed osteochondroma were reviewed. Twenty-four patients underwent MRI investigation and subsequent surgical resection for potential malignant transformation. Radiology reports suggested potential malignant transformation in 11 patients (46%), but only one case (4%) had histologically confirmed malignant transformation. The discordance between MRI and histology was statistically significant ($p = 0.002$), indicating MRI overestimation.

Conclusion

MRI appears to overestimate malignant transformation in osteochondromas, with poor correlation to histology. We speculate that this discordance is due to inaccuracies in measuring the thickness of the cartilage cap during radiological (MRI) evaluation.

Level of evidence: 4

Keywords: osteochondroma, malignant transformation, chondrosarcoma

Introduction

Osteochondromas are the most common benign bone tumours and present in two variants: solitary osteochondromas and multiple hereditary exostosis (MHE).^{1,3} While the aetiology of osteochondromas is poorly understood, research into the dysregulation of the Indian hedgehog protein is currently underway, investigating its role in the pathogenesis of malignant transformation.^{4,5} Malignant transformation primarily manifests as chondrosarcoma emerging within the cartilage cap.^{1,6,7}

Osteochondromas are typically diagnosed on plain radiographs, which reveal a sessile or pedunculated bony protrusion that is continuous with the underlying cortex and medullary canal.^{1,6-8} Suspicion for malignant transformation is investigated using magnetic resonance imaging (MRI), because of its superior ability to measure the cartilage cap thickness. A cartilage cap thickness greater than 3 mm in children and 20 mm in adults is generally considered concerning, although the cut-off values vary across studies.^{1,7,9,10}

Despite the widespread use of MRI to assess of the cartilage cap, the absence of standardised, reproducible radiological measurements has made the interpretation of MRI findings challenging. Literature primarily focuses on the measurement thresholds that determine malignant transformation in osteochondroma and rarely defines how this measurement should be made.^{1-4,6-14} Other radiological features of malignant transformation include soft tissue mass with or without soft tissue calcifications, dispersed calcifications within the cartilaginous cap, bone destruction, and altered appearance on sequential studies.^{1,7,9,10}

To date no published series have investigated the diagnostic concordance between MRI features suggestive of malignant transformation and definitive histological findings in osteochondroma. This study aims evaluate the discordance between MRI and histology in patients who underwent surgical resection for presumed malignant transformation.

Methods

This single-centre retrospective cohort study was performed at a tertiary-level bone tumour and limb reconstruction unit. Institutional ethics committee approval was obtained prior to study initiation. This study included patients diagnosed with osteochondroma between January 2016 and June 2024.

Patients with radiographic or clinical features suggestive of malignant transformation underwent MRI evaluation (*Figure 1*). All MRI scans were reported by experienced academic radiologists as part of routine practice, using the department's usual diagnostic protocols. Importantly, the study did not attempt to standardise or retrospectively define the radiological criteria used to suggest malignant transformation. This was intentional: the aim was to assess how reliably such interpretation, made under real-world conditions without researcher interference, corresponds to histological outcomes. As this was a retrospective study, radiologists were unaware of the study's objectives. Inter- and intra-observer variability was unable to be assessed due to the retrospective nature of the study. Cartilage cap thickness measures were recorded from the official radiology reports as documented in the clinical record.

All surgically resected specimens were evaluated by dedicated anatomical pathologists. Histological diagnosis was considered the reference standard for determining malignant transformation.

Statistical analysis was performed using SPSS v29 (IBM Corp, Armonk, NY, USA). Parametric data were reported as mean, standard deviation (SD) and range where appropriate. Non-parametric data were described with median and range. Categorical data were described as frequencies and/or counts, with a 95% confidence interval (CI) where appropriate. Fisher's exact test was used to detect significant differences between categorical data.

Results

A total of 42 patients with radiographically diagnosed osteochondroma were reviewed. There were 30 males and 12 females, with a median age of 19.5 years (IQR 15–31). Out of the 42 patients, 38/42 (91%) patients were diagnosed with solitary osteochondroma, while 4/42 (10%) patients had MHE. The most affected anatomical sites were the tibia (14/42, 33%) and femur (12/42, 29%). Most patients 39/42 (93%) initially presented with a palpable mass or swelling. Additional symptoms included pathological pain at rest 24/42 (57%), mechanical symptoms 12/42 (29%), and mass effect 12/42 (29%). The patients' demographics and lesion characteristics are summarised in *Table 1*.

Of the 42 included patients, 27 (64%) underwent MRI evaluation based on concerning clinical or radiographic features. Among

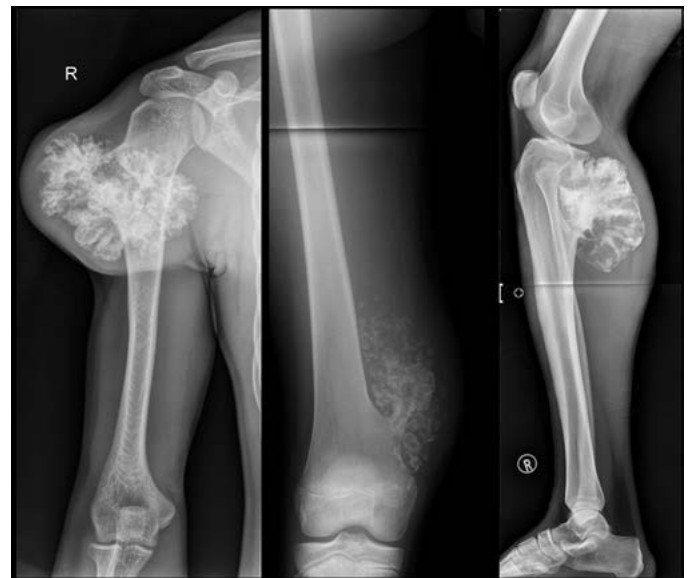

Figure 1: Examples of osteochondromas collected from this present study that raised suspicion of possible malignant transformation, and subsequently underwent MRI investigation

these, 12 patients (44%) had MRI findings suggestive of malignant transformation. Three patients were excluded from histological comparison: one declined surgery and two did not have histology results at the time of data collection. Therefore, nine patients with radiologically concerning features underwent surgery and had histological results available. Of these, one patient (11%) had confirmed malignant transformation (high-grade chondrosarcoma), while the remaining eight (89%) were confirmed to be benign on histology.

The remaining 15 patients (36%) had benign-appearing lesions. Of these, 11 (73%) underwent surgical resection for mechanical symptoms, with histology confirming benign osteochondromas in all cases.

In total, 24 patients underwent both MRI investigation and surgical resection. The age range among this group was 9–70 years with a median age of 19.5 years (IQR 15–31). Of these, 22 (92%) had no histological evidence of malignancy. One patient had benign histology and was found intraoperatively to have bone erosion from a brachial artery aneurysm. One patient had histological confirmation of malignant transformation to high-grade chondrosarcoma.

Table 1: The demographics of the patients diagnosed with osteochondromas

Demographics	n = 42
Male sex (% , n)	71 (30)
Female sex (% , n)	29 (12)
Age in years (mean, STD)	23.93 (±14.6)
Side of presentation (% , n)	
Right	50 (21)
Left	48 (20)
Bilateral	2 (1)
Lesions (% , n)	
Single	90 (38)
Multiple	10 (4)
Lesion type (% , n)	
Pedunculated	52 (22)
Sessile	48 (20)

Data reported as mean, percentage or as frequencies with counts in parenthesis

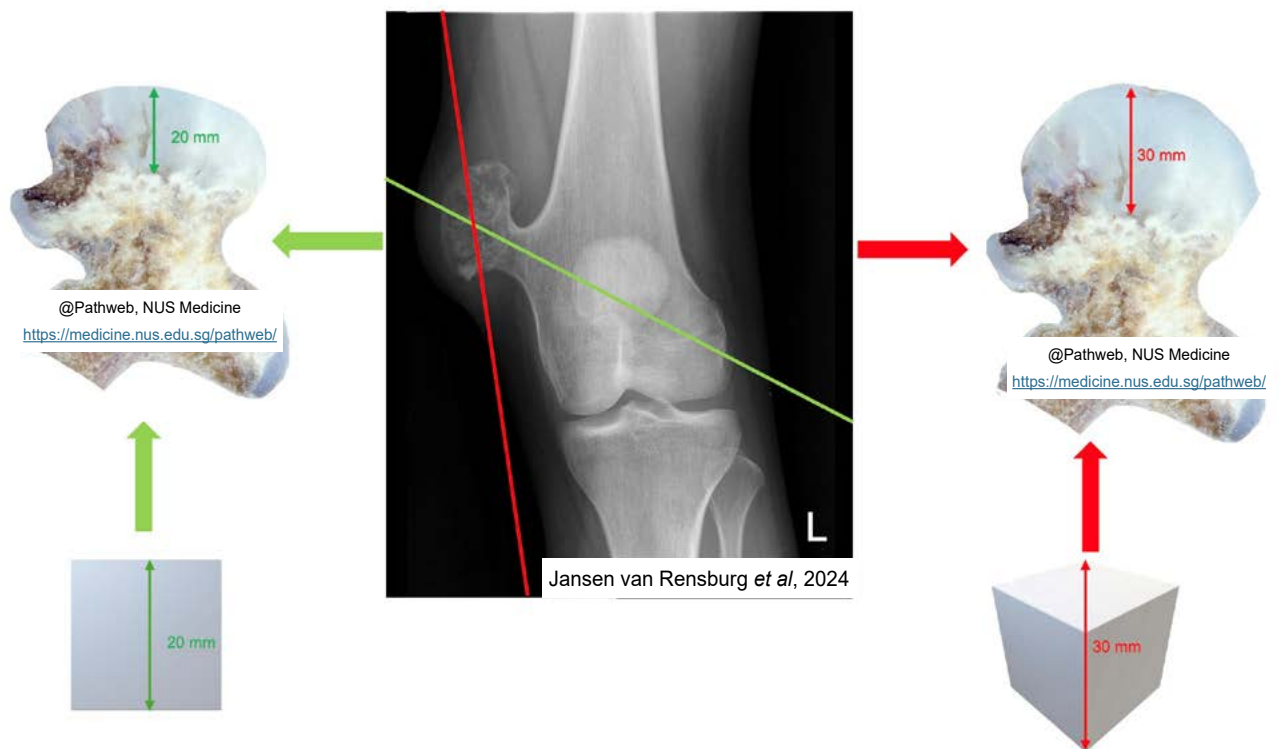


Figure 2: Oblique angle of the lesion resulting in inaccurate measurement and overestimation of cartilage cap thickness

This represents significant discordance between concerning MRI features of malignant transformation and histological confirmation. The positive predictive value of MRI for malignant transformation in this cohort was 9%.

A total of 37/42 (88%) patients underwent surgical osteochondroma excision. Histology was for 35/37 (95%) cases. Only one case (3%) was found to be malignant, in line with published malignancy rates.

Discussion

This study demonstrates a significant discordance between MRI findings and histological confirmation of malignant transformation in patients with osteochondroma. Among patients with no concerning features on plain radiographs, no histological evidence of malignant transformation was found. Among patients with concerning features reported on MRI, only one case had evidence of malignant transformation on histological examination, indicating a notable tendency of MRI to overestimate the presence of malignant transformation of these lesions. In this study, the authors attribute this discrepancy to inaccuracies in measuring the cartilage cap thickness during radiological evaluation conducted with MRI investigation.

According to Ramavathu et al. malignant transformation occurs in 1% of solitary osteochondroma cases and 3–5% of HME cases.⁷ Two studies conducted in China have reported on the incidence rate of malignant transformation of osteochondroma. Zheng et al. documented an incidence rate of 2.4%, and Tong et al. reported an incidence rate of 1.1%.^{15,16} This current study is in keeping with the literature in reporting low rates of malignant transformation of osteochondroma.^{15,16}

The cartilaginous cap serves as the origin for neoplastic progression into secondary chondrosarcoma.^{1,17} To assess for malignant transformation, measurement of the cartilage cap thickness using MRI investigation acts as a pivotal criterion.^{6,8,17,18} Despite the debate regarding threshold values for cartilage cap thickness to indicate malignant transformation, the lack of standardisation in measurement technique seems more problematic.^{1-4,6-14}

Ramavathu et al. produced a sensitivity and specificity test of 100% and 98% respectively, using 20 mm cartilage cap thickness as the cut-off value for differentiation between benign osteochondroma and malignant transformation.⁷ In this present study, the MRI evaluation produced a high sensitivity (100%), but a low specificity (57%) in detecting features of malignant transformation when compared to the histological findings. Deckers et al. reported several studies wherein MRI findings corresponded with histopathological findings.¹⁸ However, in this study there is no correlation between MRI findings and histopathological findings of malignant transformation of osteochondroma.

Bernard et al. proposed the technique for measuring the cartilage cap perpendicular to the tidemark, excluding cartilage crevasses.¹⁷ However, there are several potential problems with this method for measuring the cartilage cap size. These potential problems include 1) variability in identifying the tidemark which serves as a crucial reference point. Therefore, 2) measuring the thickest portion of the cartilage perpendicular to the tidemark can be challenging, especially if the tidemark is not well-defined. Lastly, 3) difficulty in differentiating the cartilage cap from surrounding structures could result in inaccurate measurement and subsequent overestimation of cartilage cap size. As Bernard et al. stated: 'overlying bursa results in false-positive thickening of the cartilage cap when measured on CT'.¹⁷

This study proposes an additional consideration or possible explanations for the inaccurate interpretations of malignant findings on MRI and the low confirmed malignancy rate on histology. To minimise inaccurate measurement of cartilage cap thickness, it is critical to ensure a true axial and true sagittal view of the lesion is obtained during MRI investigation. As described by Bernard et al., an axial cut is used in order to identify the tidemark which serves as a crucial reference point.¹⁷ Figure 2 illustrates the so-called projection effect: the surface area of a lesion increases when the lesion has an oblique view rather than a true axial view. The term 'projection effect' is used in physics and mathematics to describe an increase surface area of the object (the increase in projected area is proportional to the cosine of the tilt angle).¹⁹

In radiology, it is described as a parallax effect – whenever the object is placed off-centre or tilted relative to the centre of the beam, the resulting projection may be distorted.²⁰ Measuring the lesion at an oblique angle may lead to inaccurate measurements, potentially creating a false impression of malignant transformation.

Given the high rate of false-positive MRI findings, clinicians should interpret concerning imaging features cautiously and avoid using MRI in isolation to justify surgical excision. Incorporating clinical symptoms, lesion progression and radiographic changes offers a more balanced approach to managing suspected malignant transformation.

This study has several limitations, primarily due to the relatively small sample size of patients diagnosed with osteochondroma. The retrospective design introduces inherent constraints, including the lack of standardised imaging interpretation and the inability to assess inter- and intra-observer variability. Additionally, the potential for selection bias cannot be excluded, and the single-centre setting may limit the generalisability of our findings to broader populations.

Conclusion

Malignant transformation of osteochondroma remains rare but clinically significant. This study highlights a notable discordance between MRI findings suggestive of malignancy and histological confirmation, with MRI demonstrating poor specificity. The overestimation of malignancy risk based on imaging alone may lead to unnecessary surgical intervention and patient anxiety.

Our findings underscore the need for standardised, reproducible criteria for assessing cartilage cap thickness. Until such protocols are established, clinicians should interpret MRI findings in conjunction with clinical symptoms and radiographic progression to guide management.

Ethics statement

The authors declare that this submission is in accordance with the principles laid down by the Responsible Research Publication Position Statements as developed at the 2nd World Conference on Research Integrity in Singapore, 2010.

Prior to the commencement of the study ethical approval was obtained from the following ethical review board: Stellenbosch University Health Research Ethics Committee (N24/04/048). All procedures were in accordance with the ethical standards of the responsible committee on human experimentation (institutional and national) and with the Helsinki Declaration of 1975, as revised in 2008. Due to the retrospective nature of this study, this article does not contain any studies with human or animal subjects. For this study, formal consent was not required.

Declaration

The authors declare authorship of this article and that they have followed sound scientific research practice. This research is original and does not transgress plagiarism policies.

Author contributions

AJvR: data capture, data analysis, first draft preparation, design of testing set-up, manuscript preparation, manuscript revision

KS: manuscript preparation, manuscript revision

EJF: manuscript preparation, manuscript revision

RGV: manuscript preparation, manuscript revision

NF: study conceptualisation, data capture, manuscript preparation, study design, manuscript revision

ORCID

Jansen van Rensburg A  <https://orcid.org/0000-0001-6341-0734>

Siwicka K  <https://orcid.org/0009-0004-8297-0672>

Fúzy EJ  <http://orcid.org/0000-0002-2998-0829>

Venter RG  <https://orcid.org/0000-0003-0022-6969>

Ferreira N  <https://orcid.org/0000-0002-0567-3373>

References

1. Murphey MD, Choi JJ, Kransdorf MJ, Flemming DJ, Gannon FH, Pathology O. Imaging of Osteochondroma: Variants and Complications with Radiologic-Pathologic Correlation *RadioGraphics*. 2000;20(5):1407-1434.
2. Wu Y-Q, Heutink P, de Vries BBA, Sandkuijl LA, van den Ouweland AM, Niermeijer MF, Galjaard H, Reyniers E, Willems PJ, Halley DJ. Assignment of a second locus for multiple exostoses to the pericentromeric region of chromosome 11. *Hum Mol Genet*. 1994;3(1):167-171.
3. Hecht JT, Hogue D, Strong LC, Hansen MF, Blanton SH, Wagner M. Hereditary multiple exostosis and chondrosarcoma: linkage to chromosome 11 and loss of heterozygosity for EXT-linked markers on chromosomes 11 and 8. *Am J Hum Genet*. 1995;56(5):1125-31.
4. Bellaïche Y, The I, Perrimon N. *Tout-velu* is a *Drosophila* homologue of the putative tumour suppressor EXT-1 and is needed for Hh diffusion. *Nature*. 1998;394(6688):85-88.
5. Jones KB, Morcuende JA. Of hedgehogs and hereditary bone tumors: re-examination of the pathogenesis of osteochondromas. *Iowa Orthop J*. 2003;23:87-95.
6. Tepelenis K, Papathanakos G, Kitsouli A, et al. Osteochondromas: An updated review of epidemiology, pathogenesis, clinical presentation, radiological features and treatment options. *In Vivo (Brooklyn)*. 2021;35(2):681-691.
7. Ramavathu KVM, Atwal SS. Postgraduate Education Imaging of Osteochondromas Suspected of Malignant Transformation. *International Journal of Anatomy, Radiology and Surgery*. 2015;4(2):11-13.
8. Kitsoulis P, Galani V, Stefanaki K, Paraskevas G, Karatzias G, Agnantis NJ, Bai M. Osteochondromas: review of the clinical, radiological and pathological features. *In Vivo*. 2008;22(5):633-46.
9. Ozaki T, Hillmann A, Blasius S, Link T, Winkelmann W. Multicentric malignant transformation of multiple exostoses. *Skeletal Radiol*. 1998;27(4):233-236.
10. de Stadler JL, Kruger N, Singh S, Banderker E, Dix-Peek S, Pillay K. Malignant transformation in an 11-year-old child with multiple hereditary exostosis. *South African Orthopaedic Journal*. 2021;20(3):183a-183e.
11. De Andrea CE, Kroon HM, Wolterbeek R, et al. Interobserver reliability in the histopathological diagnosis of cartilaginous tumors in patients with multiple osteochondromas. *Modern Pathology*. 2012;25(9):1275-1283.
12. Bailescu I, Popescu M, Sarafoleanu LR, Bondari S, Sabetay C, Mitroi MR, Tuculina MJ, Albulescu DM. Diagnosis and evolution of the benign tumor osteochondroma. *Exp Ther Med*. 2022;23(1):103.
13. Jilowa S, Paliwal P, Kapur A, Verma GC. Exostosis of Rib: Case Report of an Extremely Rare Giant Osteochondroma at an Unusual Site, Radiopathological Correlation with Brief Review of Literature. *Indian J Radiol Imaging*. 2021;31(3):740-744.
14. Vlok SCS, Wagener GWW, Zaharie D. Secondary chondrosarcoma: Malignant transformation of pre-existing hereditary and non-hereditary cartilaginous lesions. *South African Journal of Radiology*. 2014;18(2).
15. Zheng L, Zhang H, Huang J, Tang J, Liu L, Jiang Z. Clinicopathologic features of osteochondroma with malignant transformation. *Zhonghua Bing Li Xue Za Zhi*. 2009;38(9):609-13.
16. Tong K, Liu H, Wang X, et al. Osteochondroma: Review of 431 patients from one medical institution in South China. *J Bone Oncol*. 2017;8:23-29.
17. Bernard SA, Murphey MD, Flemming DJ, Kransdorf MJ. Improved differentiation of benign osteochondromas from secondary chondrosarcomas with standardized measurement of cartilage cap at CT and MR imaging. *Radiology*. 2010;255(3):857-865.
18. Deckers C, Steyvers MJ, Hannink G, Schreuder HWB, de Rooy JWJ, Van Der Geest ICM. Can MRI differentiate between atypical cartilaginous tumors and high-grade chondrosarcoma? A systematic review. *Acta Orthop*. 2020;91(4):471-478.
19. Ramos-Ceja ME, Pacaud F, Reiprich TH, Migkas K, Lovisari L, Schellenberger G. Projection effects in galaxy cluster samples: insights from X-ray redshifts. *Astron Astrophys*. 2019;626:A48.
20. Obiwulu AU, Erusiafe N, Olopade MA, Nwokolo SC. Modeling and estimation of the optimal tilt angle, maximum incident solar radiation, and global radiation index of the photovoltaic system. *Heliyon*. 2022;8(6):e09598.